

Severe recessive dystrophic epidermolysis bullosa (RDEB): information for families

This information sheet from Great Ormond Street Hospital (GOSH) explains about severe recessive dystrophic epidermolysis bullosa and how it can be managed. It also contains suggestions for making everyday life more comfortable.

Please note: This information sheet suggests some commercial products that can be helpful in managing epidermolysis bullosa – including them in this information sheet does not mean that they are recommended by GOSH and alternative products may be available.

Epidermolysis bullosa (EB) is the term used to describe a number of rare genetic conditions which cause the skin to blister and shear in response to minimal friction and trauma. There are four broad categories of EB: EB simplex, junctional EB, dystrophic EB and Kindler syndrome. Within each of these categories there are several different subtypes. If someone has one form of EB they cannot develop any of the others.

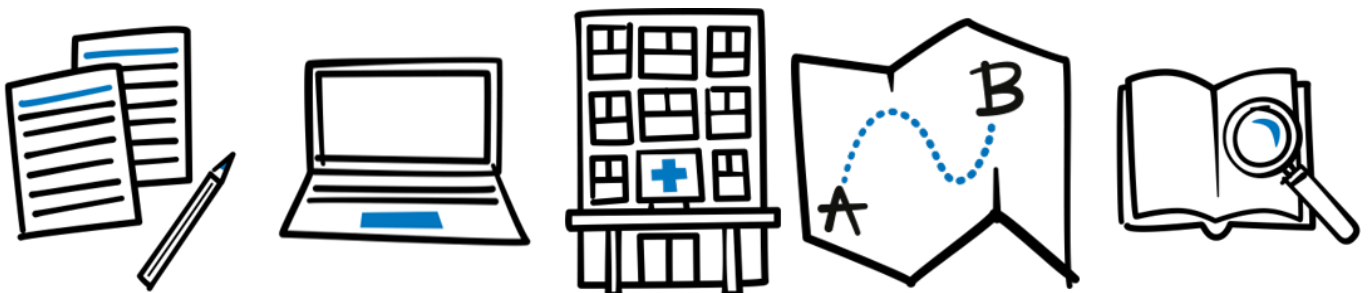
We have two copies of every gene, each inherited from one of our parents. DEB can be inherited dominantly or recessively.

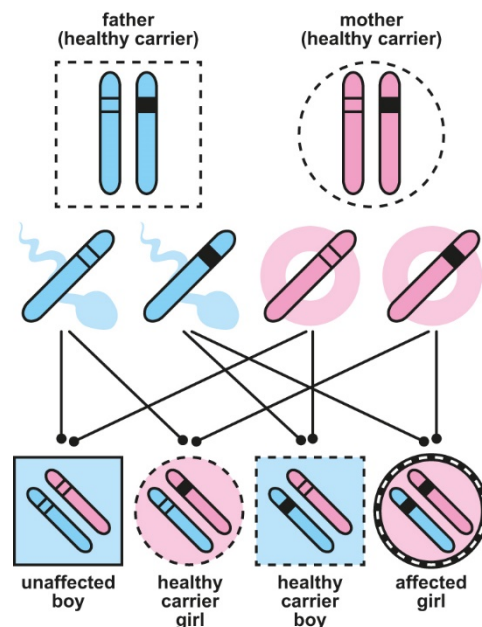
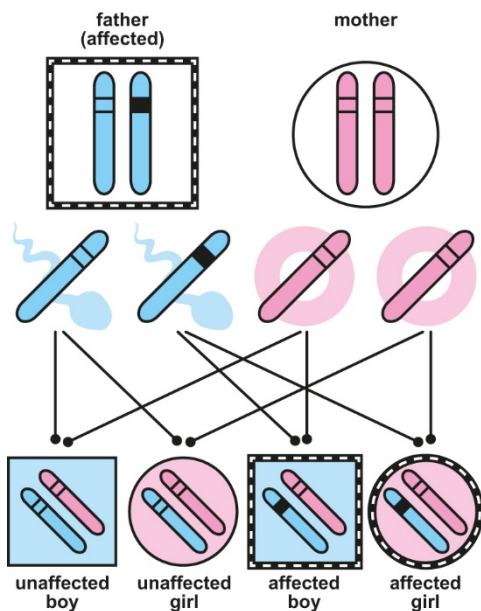
Dominant inheritance

In a dominant condition, an affected individual has a 50 per cent (1 in 2) chance of passing the affected gene to their child. The dominant gene 'overwhelms' the non-affected gene. There is no carrier status in a dominant condition.

What causes dystrophic EB (DEB)?

EB is a genetic condition. Genes determine characteristics such as eye colour and also our health. A genetic mutation means a change similar to a spelling mistake has happened and this change makes the gene faulty.





Very occasionally, an affected individual will develop the condition with no family history and this is said to be a new mutation developed spontaneously (out of the blue) rather than inheriting it.

Recessive inheritance

If a person has a one faulty copy and the other is unaffected, they are said to be a 'carrier' of the condition, in this case a carrier of dystrophic EB. They do not usually have any symptoms of the condition.

If their partner is also a carrier for dystrophic EB there is a 25 per cent (1 in 4) risk in every pregnancy that the baby will inherit both faulty copies of the gene and therefore have dystrophic EB.

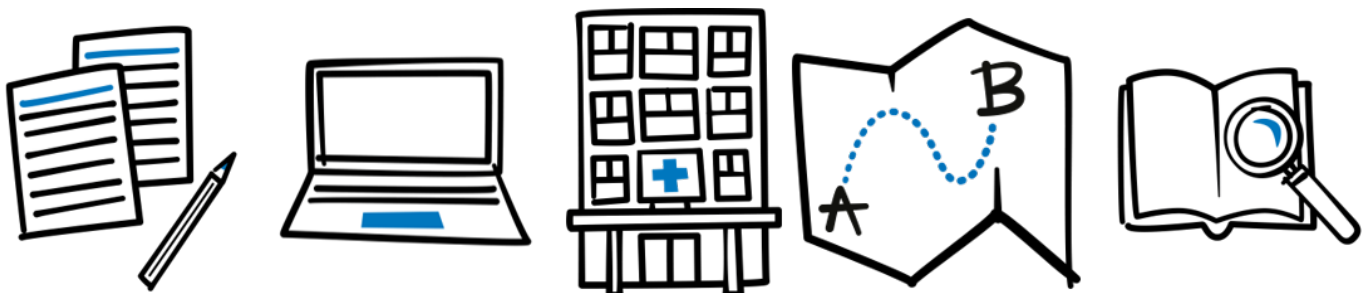
The more severe forms of DEB, in general, being inherited recessively. Everyone who has DEB (whether inherited in a dominant or recessive manner) has a reduction in, or complete absence of, an important protein called collagen VII. Collagen VII forms a part of anchoring fibrils, which are present in the skin. Anchoring fibrils act rather like Velcro® hooks holding the layers of the skin together.

How is EB diagnosed?

In the majority of cases, the type of EB can be determined by analysis of a skin biopsy (tiny sample of skin) under a microscope. Blood samples are also taken from the child and parents to look for the specific gene changes.

Is there a cure?

Not yet, but research continues. There is still a long way to go, but an effective treatment to prevent the skin problems may ultimately be possible.



How serious is RDEB?

The extent of skin fragility is extremely variable, depending on whether the faulty gene is linked to mild or severe disease and whether the affected individual has completely absent or reduced collagen VII.

Types of RDEB

Recessive dystrophic EB – severe (RDEB-S)

In this form of EB, the skin is extremely fragile, often with extensive blistering and wounds. There is usually no collagen VII present. Wounds tend to heal with a scar that can lead to contractures and impaired movement, particularly affecting the hands. The linings of the mouth and the oesophagus (swallowing tube) are also fragile leading to problems with feeding and nutrition.

Recessive dystrophic EB –intermediate

In this type, there is usually some collagen VII present in the skin. There is a tendency for the skin to blister and for wounds to develop, the extent being dependent on the amount of collagen VII present. The lining of the mouth and oesophagus are usually fragile. The hands will be scarred with some contractures but the severity is less than those with RDEB-SG.

Dystrophic EB pruriginosa (DEB-PR)

Children with DEB-PR will experience the skin fragility already described above, but will also suffer from intense itching and the resulting scratching causes further blistering.

Recessive dystrophic EB inversa (RDEB-I)

In this type of RDEB, the skin is also fragile and heals with scarring. However the damage tends to be less widespread and is often worse in the neck, groin and underarms. Hands become scarred but not severely contracted. The lining of the

oesophagus is very fragile and can cause more problems than in other types of RDEB.

There are also several other rare types of RDEB not described here.

How is RDEB managed?

Babies with RDEB may be born with large areas of skin absent especially over their feet and legs. These wounds are often sustained before birth as a result of friction from the baby kicking in the womb. Further damage can occur during the birth.

These wounds must be dressed and may take several weeks to heal. Unfortunately the resulting scarred skin often remains very fragile and will require padding even when healing has taken place. This is very important in the young baby as kicking the feet together can denude the skin repeatedly.

Handling

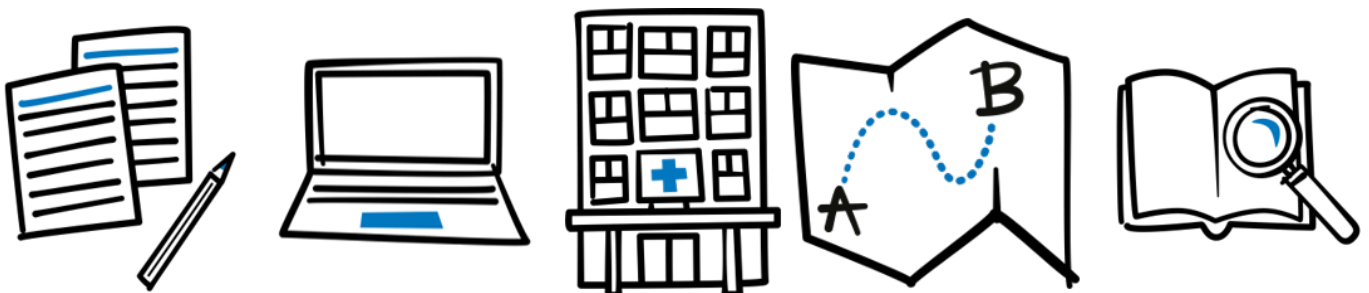
Nurse your baby on a small soft mattress that will be provided by your EB nurse. To lift the baby from the mattress, apply a 'roll and lift' technique to avoid damage from friction and shearing forces – roll the baby onto their side, place one hand behind their head, the other under the bottom, allow them to roll back onto your flat hands and lift. As you become more confident, you may not need the mattress.

Blisters

Blisters must be lanced with a hypodermic needle to prevent them from spreading. The roof should be left on the blister.

Nappy area care

Cleaning with water can sting the blisters and sores and therefore we recommend cleansing with 50/50 ointment or Emollin® emollient spray. Blisters should be lanced as above. A layer of



barrier cream such as Proshield® Plus barrier cream, reapplied at each nappy change, should protect blistered and vulnerable areas. Open wounds are covered with the dressing Intrasite® Conformable. The nappy is lined with a soft material such as Conti® SuperSoft (available on prescription) to cover the edges of the nappy to prevent friction.

Bathing

If there is extensive skin loss at birth, we recommend delaying bathing until healing has taken place. This is because bathing can be a painful process and it is difficult to protect the baby from further skin damage when all the dressings are removed at once.

Many babies enjoy bathing once the initial wounds are healed. Give prescribed painkillers before bathing and have the replacement dressings pre-cut ready to put in place. A mild antiseptic such as Octenisan® as prescribed by your EB team can be added to the water instead of commercial baby products. If you find it difficult to hold your baby in the bath, then use a towelling baby seat rather than a plastic one.

If there are a lot of dressings, it may be easier to bathe the baby with the dressings on and change them after bathing. Pat skin dry with a soft towel rather than rubbing.

Clothing

Initially, a front fastening baby grow is ideal but unless the seams are flat it will need to be worn inside out to prevent the seams from rubbing and causing blisters. Care must be taken to ensure the fasteners do not rub.

Older children can wear ordinary clothes if they are easy to put on and take off. Choose clothes which do not have to go over the head and without prominent seams. A range of garments is

available on prescription via your family doctor (GP) to help keep dressings in place. Skinnies® garments and Skinnies® WEB garments (www.skinnies.co.uk) are particularly useful. Other garments include the Tubifast® range.

Wound care

Open wounds must be dressed to encourage healing and stop them sticking to clothing. Suitable dressings include Urgotul® (Urgo), PolyMem® (Ferris) and a range of soft silicone dressings, which all provide protection for the skin and encourage wound healing.

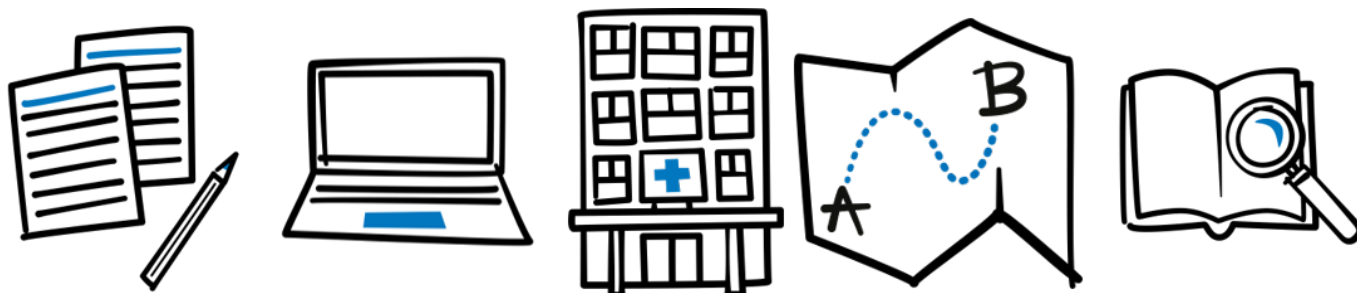
Wound management is complex but your EB team will help you to find the correct dressing regimen for your child.

As the barrier function of the skin is reduced, some wounds become infected. These can be treated with creams and ointments or specialised dressings. If your child is unwell with fever, contact your GP as treatment with antibiotics may be needed. Please ask your GP to take a wound swab before prescribing antibiotics.

If products accidentally adhere to the skin, or dressings become stuck, a non-sting medical adhesive remover, such as Appeel® (CliniMed), will remove the product painlessly and without causing further damage.

Nutrition

Babies may be reluctant to feed due to soreness from blisters in the mouth. A Haberman® (Special Needs) feeder is often helpful. Application of teething gels to the teat or directly to the mouth prior to feeding or a preparation such as Gelclair® further reduces pain. Breastfeeding is often possible although the face may need to be protected with a layer of emollient to reduce friction from rooting.



Due to increased nutritional needs from wound healing, additional protein and calories may be prescribed under the guidance of a specialist dietitian.

If there has been a lot of blistering in the lining of the oesophagus this can heal leaving a scar which may cause narrowed areas called strictures that make swallowing more difficult. These can be stretched by a procedure called an oesophageal dilatation (OD) that is performed by a specialist team under general anaesthetic. This is generally very effective although may need to be repeated regularly.

If your child is not able to take enough nutrients to grow then feeding can be supplemented by inserting a gastrostomy tube into the stomach that enables additional feed to be given.

Constipation is a common problem with all types of EB, often resulting from blistering and soreness around the bottom. Constipation may be further compounded by side effects from pain medicines. Treatment with laxatives may be needed.

Pain management

Blisters and wounds can be painful but children's need for pain relieving medicines varies greatly.

Pain management is complex and needs constant readjustment. Your EB team will help with this and will refer to a specialist paediatric pain team if extra assistance is needed.

Teeth

The teeth develop normally but scarring inside the mouth can lead to overcrowding of the teeth that in combination with fragile gums can make tooth cleaning difficult and restorative treatment and extractions are often necessary. Brushing with a soft toothbrush should be encouraged and fluoride supplements may be prescribed.

Regular assessment by a specialist dentist experienced in EB care will ensure optimal preventative care and treatment is given.

Eyes

Blistering of the surface of the eye can be a problem. Rubbing the eyes can trigger this painful condition, but blisters often result from dry eyes caused by a reduced tear film.

Eye drops and ointments prescribed by an ophthalmologist experienced in the care of children with EB can help keep the eyes moist and reduce the incidence of blistering. Once an abrasion has occurred, the lubricants should be replaced with antibiotic eye drops.

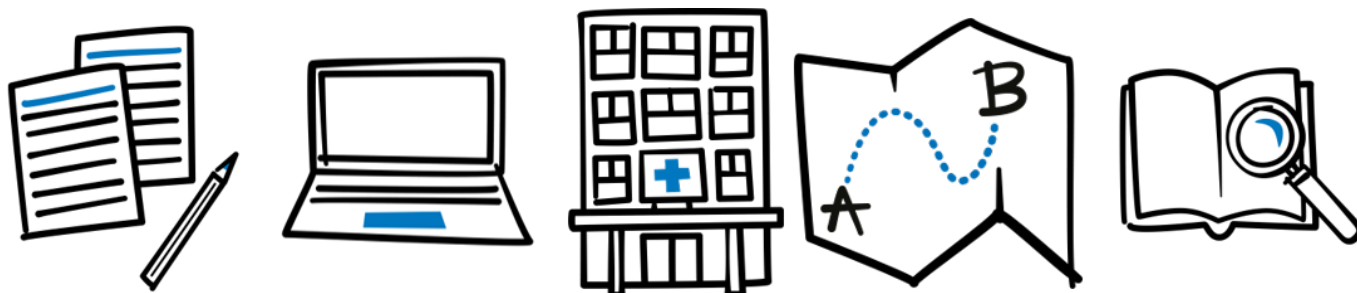
Abrasions in the eye are painful and pain-relieving medicines should be given while waiting for assessment by the ophthalmologist. The child may prefer to keep their eyes closed and avoid bright light while the abrasion is healing. Never allow the eye to be forced open in order to examine it or further damage may result.

Hands

In all forms of RDEB, the hands become scarred. In those with RDEB-SG, the hands have a tendency to contract leading to the fingers becoming webbed and forced into a fist. This can be delayed by splinting the hands under the guidance of an EB occupational therapist. In many children, webbing can be avoided by bandaging through the web spaces in between the fingers. There is a DEBRA booklet available that explains care of the hands in more detail.

Nails

Finger and toenails may be missing from birth or may be lost over the first few months of life. Sometimes the nail will re-grow or it may be lost permanently. Those with mild forms of DEB may



not lose the nails, but thickening and distortion can result if the nail suffers trauma

Itch

While those with RDEB pruriginosa experience itching most of all, this is a problem that affects all types of EB. Inevitably, itching leads to scratching which damages the fragile skin. Wounds that are almost healed are particularly itchy.

Although it is difficult to control itch the following suggestions may be helpful:

- Try to keep the environmental temperature cool, using fans (directed away from the face to avoid drying the eyes or use a non-buffering Dyson® fan) or an air conditioning unit.
- Dry skin tends to be itchier, so apply a bland moisturiser as suggested by your EB specialist.

Later complications

There is an increased risk of developing a type of cancer called squamous cell carcinoma in older children and adults. It is important that all the skin is examined regular by an EB specialist to detect these early so treatment can be offered.

Is it possible to test for EB before birth?

In most cases, prenatal testing is available for parents who are known to be carriers of recessive dystrophic EB. The test is called chorionic villous sampling (CVS) and involves a small piece of the placenta being taken for genetic testing after the 11th week of pregnancy. It may also be possible to test before pregnancy is established using IVF techniques and testing the embryos before they are implanted.

Both tests are only possible if specific gene changes have been identified. In a very small minority where there is insufficient information to interpret the test, a later test (after the 15th week of pregnancy) may be offered. This involves analysis of a small piece of skin taken from the baby.

Further information and support

EB team at Great Ormond Street Hospital (GOSH) – 020 7829 7808

DEBRA is the national charity that supports individuals and families affected by Epidermolysis Bullosa (EB) – a painful genetic skin blistering condition which, in the worst cases, can be fatal. DEBRA provides information, practical help and professional advice to anybody living or working with EB, including individuals, families, carers and healthcare professionals, and funds research into the condition. To find out more about how DEBRA can support you, please visit www.debra.org.uk.

