

Truncus Arteriosus

Type I

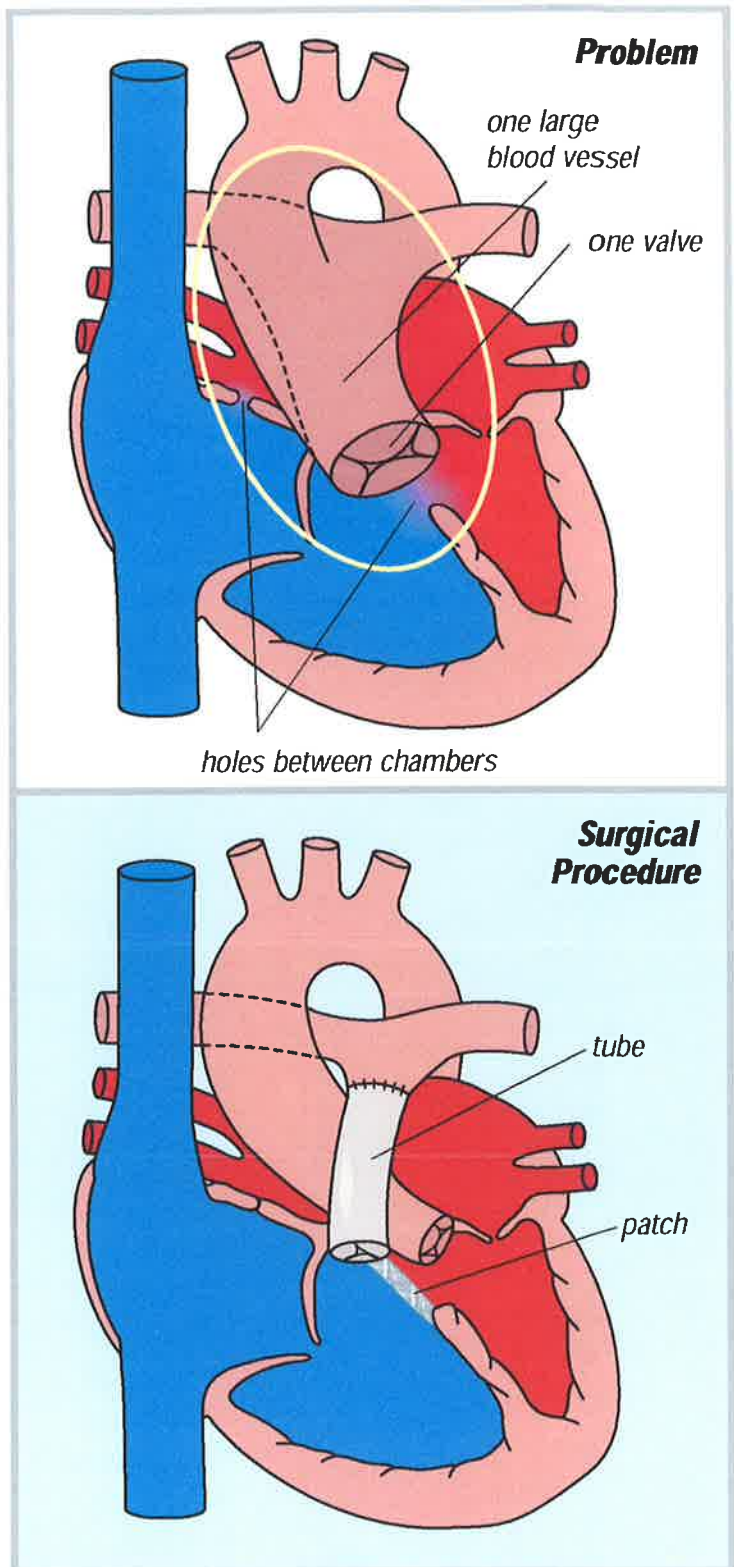
One large blood vessel (truncus) with a single valve leaves the heart. This blood vessel has branches that go to the lungs, body and coronary arteries. There is almost always a large hole between the bottom two chambers of the heart (ventricular septal defect).

There are several types of truncus arteriosus (TA):

- Type I - 60% of all cases of TA are this type.
- Type II - 20% of all cases of TA are this type.
- Type III - 10% of all cases of TA are this type.

Type I is corrected by closing the hole between the bottom two chambers of the heart so that the blood from the bottom left chamber goes into the truncus. This is closed with a patch. A connection is often made between the bottom right heart chamber and the branch pulmonary arteries going to the lungs. The connection is made with a tube that contains a valve (valved conduit, Rastelli repair).

Surgery is done through a median sternotomy (chest) incision.



Truncus Arteriosus

Types II-III

One large blood vessel (truncus) with a single valve leaves the heart. This blood vessel has branches that go to the lungs, body and coronary arteries. There is almost always a large hole between the bottom two chambers of the heart (ventricular septal defect).

There are several types of truncus arteriosus (TA):

- Type I - 60% of all cases of TA are this type.
- Type II - 20% of all cases of TA are this type.
- Type III - 10% of all cases of TA are this type.

Types II and III are similar enough to group together.

Types II and III are corrected by closing the hole between the bottom two chambers of the heart so that the blood from the bottom left chamber goes into the truncus. This is closed with a patch. A connection is often made between the bottom right heart chamber and the branch pulmonary arteries going to the lungs. The connection is made with a tube that contains a valve (valved conduit, Rastelli repair). The areas on the truncal vessel where the branch pulmonary arteries have been removed are patched closed.

Surgery is done through a median sternotomy (chest) incision.

